

VISION ACADEMY VIEWPOINT

The Vision Academy is a partnership between Bayer and ophthalmic specialists, established with the aim of addressing key clinical challenges in the field of retinal diseases: www.visionacademy.org.

Characterization of Macular Neovascularization Subtypes in Age-Related Macular Degeneration to Optimize Treatment Outcomes

Background

Despite the efficacy of anti-vascular endothelial growth factor (VEGF) therapies, long-term treatment and follow-up are necessary to maintain visual gains in patients with neovascular age-related macular degeneration (nAMD),¹ with more than 85% of patients requiring multiple injections of anti-VEGF therapy after the initial treatment doses.² However, a lack of consensus recommendations results in varied patient management in the subsequent treatment period. Many efforts have been made to classify nAMD pathology and the different types of macular neovascularization (MNV).³⁻⁵ Recent developments in imaging techniques have improved the visualization of the retina, allowing more precise MNV localization and classification.⁶ Many ophthalmology centers now use multimodal imaging in routine practice and are therefore able to classify MNV subtypes before deciding on a specific treatment regimen. Accurately assessing MNV subtypes can provide information on expected prognosis and aid in optimizing treatment. Furthermore, a clearly defined classification of MNV can predict functional and anatomic outcomes after treatment and allows the individualization of treatment regimens according to a patient's MNV subtype.

A review of the literature and available evidence⁷ was conducted to:

- Describe and define MNV subtypes in nAMD
- Provide recommendations on tailoring treatments to the different MNV subtypes

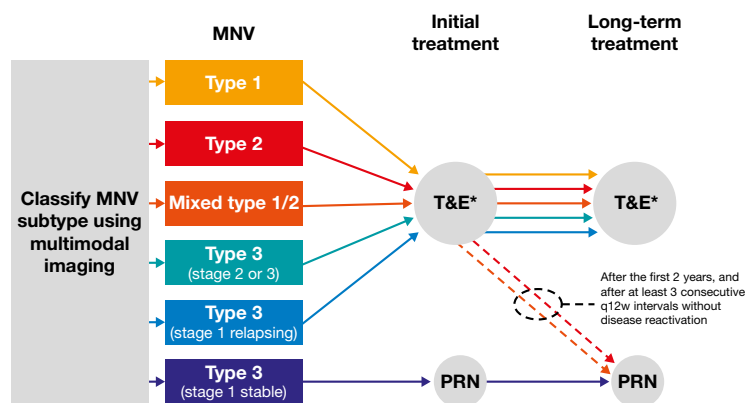
Endorsed by the Vision Academy
in November 2022.

Date of review: November 2024

 Variations in opinion

Viewpoint

To optimize functional outcomes in patients with nAMD, the treatment regimen should be individualized for each patient, according to the type of MNV. In all cases, treatment should be initiated promptly, as early as possible. Multimodal imaging, ideally including optical coherence tomography (OCT), fluorescein angiography, and indocyanine green angiography, although this may not always be feasible, should be used in conjunction to accurately classify the lesion as type 1, 2, or 3 MNV or mixed. The decision tree below was developed to guide tailoring of the treatment regimen according to MNV subtype.



*Fixed should not be the treatment regimen of choice but can be used in some instances where T&E is not feasible due to resource or organizational constraints. PRN, *pro re nata* (as needed); q12w, once every 12 weeks; T&E, treat-and-extend.

1. Patients with type 1 lesions should be treated with an individualized treat-and-extend (T&E) regimen with extended treatment and observation periods

- Type 1 lesions often require more anti-VEGF injections than other types of MNV⁸
- As long-term outcomes are typically better than for other MNV subtypes,⁸ an individualized regimen such as T&E should be proposed as a priority to reduce patient burden
 - A fixed-dose regimen, although not the treatment of choice, could be proposed when T&E is not feasible due to resource or organizational constraints, depending on the observed time to recurrence
- Prolonged treatment and observation periods are necessary to avoid the development of polypoidal choroidal vasculopathy and related complications

Vision Academy Viewpoints are intended to raise awareness of a clinical challenge within ophthalmology and provide an expert opinion to engage in further discussion.

They can be downloaded from <https://www.visionacademy.org/resource-zone/resources/all>

The Vision Academy is a group of over 100 international ophthalmology experts who provide guidance for best clinical practice through their collective expertise in areas of controversy or with insufficient conclusive evidence. The Vision Academy is funded and facilitated by Bayer. This document was prepared on behalf of the Vision Academy by Thibaud Mathis, Frank G. Holz, Sobha Sivaprasad, Young Hee Yoon, Nicole Eter, Lee-Jen Chen, Adrian Koh, Eduardo Cunha de Souza, and Giovanni Staurenghi. The opinions and guidance of the Vision Academy outputs are those of its members and do not necessarily reflect the opinions of Bayer.

Always refer to local treatment guidelines and relevant prescribing information.

November 2022 | MA-PFM-OPHT-ALL-1075-1

References

1. Mehta H, Kim LN, Mathis T *et al.* Trends in real-world neovascular AMD treatment outcomes in the UK. *Clin Ophthalmol* 2020; 14: 3331–3342.
2. Kodjikian L, Souied EH, Mimoun G *et al.* Ranibizumab versus bevacizumab for neovascular age-related macular degeneration: results from the GEFAL noninferiority randomized trial. *Ophthalmology* 2013; 120 (11): 2300–2309.
3. Gass JD. Biomicroscopic and histopathologic considerations regarding the feasibility of surgical excision of subfoveal neovascular membranes. *Trans Am Ophthalmol Soc* 1994; 92: 91–111; discussion 111–116.
4. Grossniklaus HE and Gass JDM. Clinicopathologic correlations of surgically excised type 1 and type 2 submacular choroidal neovascular membranes. *Am J Ophthalmol* 1998; 126 (1): 59–69.
5. Spaide RF, Jaffe GJ, Sarraf D *et al.* Consensus nomenclature for reporting neovascular age-related macular degeneration data: consensus on neovascular age-related macular degeneration nomenclature study group. *Ophthalmology* 2020; 127 (5): 616–636.
6. Freund KB, Zweifel SA and Engelbert M. Do we need a new classification for choroidal neovascularization in age-related macular degeneration? *Retina* 2010; 30 (9): 1333–1349.
7. Mathis T, Holz FG, Sivaprasad S *et al.* Characterisation of macular neovascularisation subtypes in age-related macular degeneration to optimise treatment outcomes. *Eye* 2022; Epub ahead of print. doi: 10.1038/s41433-022-02231-y.
8. Mrejen S, Jung JJ, Chen C *et al.* Long-term visual outcomes for a treat and extend anti-vascular endothelial growth factor regimen in eyes with neovascular age-related macular degeneration. *J Clin Med* 2015; 4 (7): 1380–1402.
9. Daniel E, Pan W, Ying GS *et al.* Development and course of scars in the Comparison of Age-Related Macular Degeneration Treatments Trials. *Ophthalmology* 2018; 125 (7): 1037–1046.
10. Cohen SY, Oubraham H, Uzzan J *et al.* Causes of unsuccessful ranibizumab treatment in exudative age-related macular degeneration in clinical settings. *Retina* 2012; 32 (8): 1480–1485.
11. Baek J, Lee JH, Kim JY *et al.* Geographic atrophy and activity of neovascularization in retinal angiomatous proliferation. *Invest Ophthalmol Vis Sci* 2016; 57 (3): 1500–1505.
12. McBain VA, Kumari R, Townend J *et al.* Geographic atrophy in retinal angiomatous proliferation. *Retina* 2011; 31 (6): 1043–1052.
13. Farecki M-L, Gutfleisch M, Faatz H *et al.* Characteristics of type 1 and 2 CNV in exudative AMD in OCT-angiography. *Graefes Arch Clin Exp Ophthalmol* 2017; 255 (5): 913–921.
14. Nakano Y, Kataoka K, Takeuchi J *et al.* Vascular maturity of type 1 and type 2 choroidal neovascularization evaluated by optical coherence tomography angiography. *PLoS One* 2019; 14 (4): e0216304.

2) Patients with type 2 lesions should be treated according to treatment duration

- Type 2 lesions usually respond quickly to anti-VEGF therapy but are prone to the development of fibrotic scars, a risk factor for poor visual outcomes⁹⁻¹⁰
- Type 2 lesions may be treated using an intense T&E regimen in the first 2 years, extending beyond once every 12 weeks (q12w) if possible
- After the first 2 years, purely type 2 lesions can be managed with careful and frequently monitored PRN (*pro re nata*; as needed) treatment (after at least three consecutive q12w intervals without disease reactivation)

3) Patients with mixed lesions (containing both type 1 and type 2 components) should be treated proactively

- Mixed lesions can be monitored using an intense T&E regimen in the first 2 years
- After the first 2 years, mixed lesions can be managed on a case-by-case basis with T&E or careful and frequently monitored PRN treatment (after at least three consecutive q12w intervals without disease reactivation)

4) Patients with type 3 lesions should be treated according to the stage of the lesion

- Type 3, stage 1: Patients having reached stability after three initial treatment doses can be kept on a strict (monthly) PRN regimen with contralateral eye checks
 - Non-stable or relapsing stage 1: Patients should be switched to a proactive regimen (T&E or fixed)
- Type 3, stage 2 or 3: Patients should be treated with a proactive regimen
- Type 3 lesions tend to be very sensitive to anti-VEGF therapy, and treating early leads to better visual outcomes with fewer recurrences and injections
- The incidence of geographic atrophy appears to be higher in type 3 lesions than in other MNV subtypes, and the fellow eye frequently develops neovascular complications^{11,12} and should therefore be closely monitored

Further considerations

Correct assessment of the MNV subtype provides information on a patient's prognosis and helps to determine the preferred treatment regimen. Additional biomarkers, perhaps as found on OCT angiography, are needed to better optimize treatment outcomes.



The role of OCT angiography in distinguishing between MNV subtypes needs to be clarified, but there has been some success in the use of this technology to define the subtype.^{13,14} Furthermore, longer follow-up studies of treated patients with type 1–3 MNV are necessary to describe MNV transformation under anti-VEGF therapy.

Further studies are needed to determine the correlation of MNV type with additional visually relevant changes, such as photoreceptor death and retinal pigment epithelial atrophy, and whether these factors can be predicted in order to develop additional therapies. Due to the evolving treatment paradigms for polypoidal choroidal vasculopathy, this diagnosis should be considered, especially when the initial imaging is not typical of other MNV subtypes or when treatment outcomes are not as expected.

Vision Academy Viewpoints are intended to raise awareness of a clinical challenge within ophthalmology and provide an expert opinion to engage in further discussion.

They can be downloaded from <https://www.visionacademy.org/resource-zone/resources/all>

The Vision Academy is a group of over 100 international ophthalmology experts who provide guidance for best clinical practice through their collective expertise in areas of controversy or with insufficient conclusive evidence. The Vision Academy is funded and facilitated by Bayer. This document was prepared on behalf of the Vision Academy by Thibaud Mathis, Frank G. Holz, Sobha Sivaprasad, Young Hee Yoon, Nicole Eter, Lee-Jen Chen, Adrian Koh, Eduardo Cunha de Souza, and Giovanni Staurenghi. The opinions and guidance of the Vision Academy outputs are those of its members and do not necessarily reflect the opinions of Bayer.

Always refer to local treatment guidelines and relevant prescribing information.

November 2022 | MA-PFM-OPHT-ALL-1075-1