




VISION ACADEMY

people | research | education

Viewpoint: Management of subfoveal hemorrhage



Contents

Click on a section 

03

OBJECTIVES

04

BACKGROUND

11

TREATMENT

31

CLINICAL
CHALLENGES

33

VISION
ACADEMY
RECOMMENDATIONS



Objectives

To provide an overview of the challenges posed by subfoveal hemorrhage and its management

To identify areas requiring guidance

To present the recommendations of the Vision Academy on this topic

The Vision Academy provides ophthalmic specialists with a forum to share existing skills and knowledge, build best practice, and lead the wider community in the drive towards optimized, compassionate patient care.

Through their collective expertise, the Vision Academy seeks to provide guidance for best clinical practice in the management of retinal disease, particularly in areas with insufficient conclusive evidence.



QUESTION

What are the challenges posed by subfoveal hemorrhage and its management?



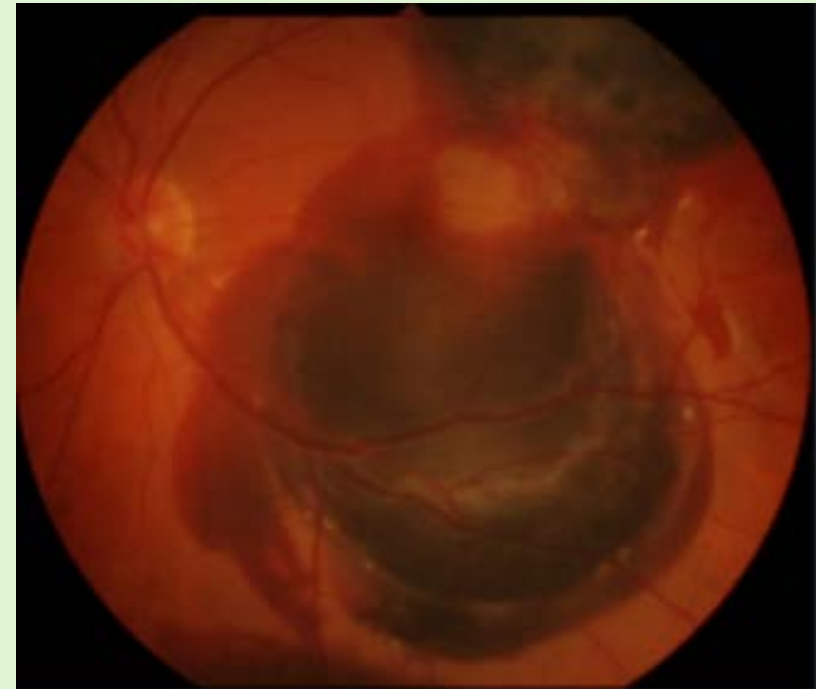
VISION ACADEMY
people | research | education

Background

Subretinal, submacular, and subfoveal hemorrhage

- **Subretinal hemorrhage**
 - Often associated with nAMD, blood from the retinal or choroidal circulation accumulates between the RPE and the photoreceptor layers¹
- **Submacular hemorrhage**
 - A subretinal hemorrhage occurring in the macular region^{1,2}
- **Subfoveal hemorrhage**
 - A subretinal hemorrhage that extends under the center of the foveal avascular zone³

Subretinal hemorrhage causes severe visual impairment when the fovea is involved¹



The Vision Academy Viewpoint addresses the management of subfoveal hemorrhage

nAMD, neovascular age-related macular degeneration; RPE, retinal pigment epithelium.

1. Stanescu-Segall D *et al. Surv Ophthalmol* 2016; 61 (1): 18–32; 2. Rishi E *et al. Indian J Ophthalmol* 2012; 60 (6): 521–525;

3. Soubrane G and Bressler NM. *Br J Ophthalmol* 2001; 85 (4): 483–495.

Subfoveal hemorrhage: When does it occur?

Frequently described as a secondary condition to AMD:

Subretinal hemorrhage frequently results from a CNVM secondary to AMD¹

Subfoveal hemorrhage occurs in approximately 5.8% of patients with exudative AMD²

As a result of CNVM conditions:

Other conditions associated with CNVMs,¹ including:

- myopia
- trauma
- ocular histoplasmosis
- angioid streaks
- macroaneurysms³

These conditions may occur in parallel with subfoveal hemorrhage

Increased risk due to certain medications and medical conditions:

Anticoagulant or antiplatelet medications were significantly associated with retinal / subretinal hemorrhages among patients with hypertension⁴

AMD, age-related macular degeneration; CNVM, choroidal neovascular membrane.

1. Driscoll S, Garg SJ. *Review of Ophthalmology* 2014. Available at: <https://www.reviewofophthalmology.com/article/managing-submacular-hemorrhage>.

Accessed July 23, 2018; 2. Cohen SY *et al. Br J Ophthalmol* 2007; 91 (9): 1173–1176; 3. Pitkänen L *et al. Acta Ophthalmol* 2014; 92 (2): 101–104;

4. Ying GS *et al. Ophthalmology* 2016; 123 (2): 352–360.



Disease mechanisms and implications

Mechanisms

Subretinal hemorrhage damages tissues through a variety of mechanisms¹

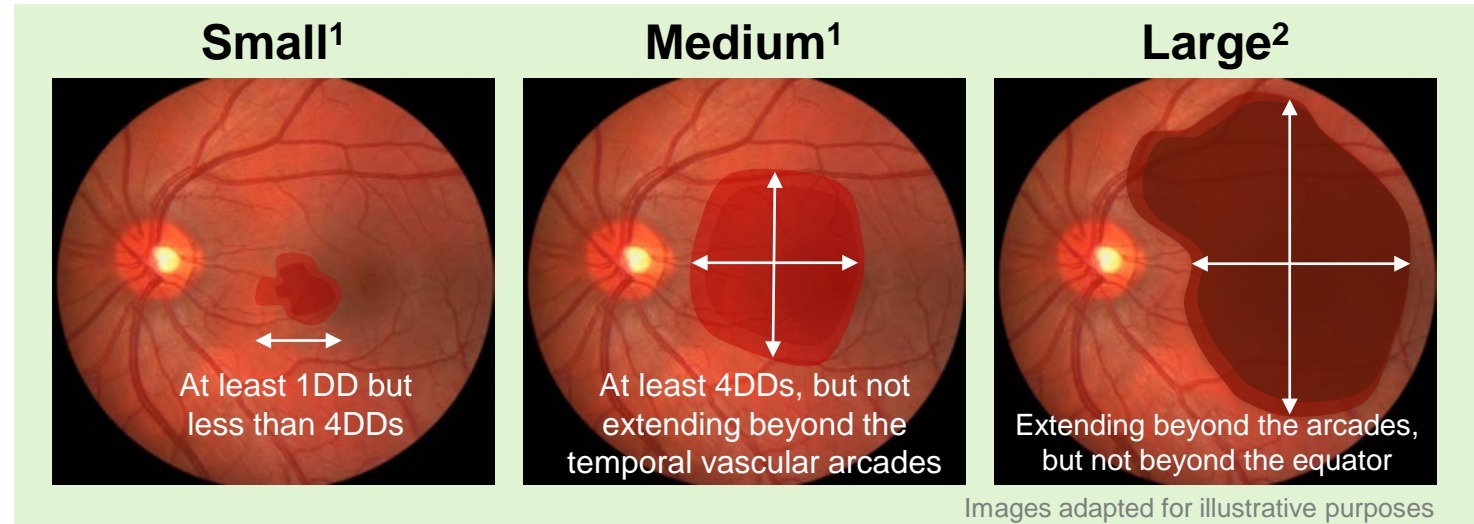
- Iron, hemosiderin, and fibrin in the blood have toxic effects on the overlying photoreceptors
- Clot retraction can shear and damage photoreceptors
- Physical separation of the photoreceptors from the RPE can lead to atrophy and disciform scar formation

Implications

- Patients with submacular / subfoveal hemorrhages experience progressive visual decline^{1,2}
- As the mechanisms of damage are time-dependent, early intervention is generally better,¹ particularly with subfoveal hemorrhage

Classification of subretinal hemorrhage is critical for treatment choice and management

Subretinal hemorrhages are often classified by size:



- Small hemorrhages can often undergo observation without intervention³
- Medium-sized hemorrhages that extend under the macula and obscure the underlying RPE can also cause significant vision loss; however they are often amenable to treatment³
- Large submacular hemorrhages often have a poor prognosis regardless of intervention³

DD, disc diameter; RPE, retinal pigment epithelium.

1. Stanescu-Segall D *et al.* *Surv Ophthalmol* 2016; 61 (1): 18–32; 2. Yiu G, Mahmoud TH. *Dev Ophthalmol* 2014; 54: 213–222;

3. Driscoll S, Garg SJ. *Review of Ophthalmology* 2014. Available at: <https://www.reviewofophthalmology.com/article/managing-submacular-hemorrhage>.

Accessed July 23, 2018.

Prognostic factors for patients with subfoveal hemorrhage

Untreated subfoveal hemorrhages lead to worse visual prognoses, indicating that early intervention is critical¹

Prognostic factors include patient age, initial BCVA, and hemorrhage thickness, diameter, and duration^{2,3}

Thickness: Thick ($\geq 500 \mu\text{m}$) subfoveal hemorrhage secondary to nAMD is a prognostic factor for dramatic vision loss⁴

Organization: Hemorrhage reflectance quantified by OCT can indicate ease of hemorrhage displacement, as it might represent hemorrhage organization⁵

Location: Hemorrhage location is also a good marker of treatment success, with hemorrhages located on the periphery of the fovea more likely to be displaced in response to treatment⁵

BCVA, best corrected visual acuity; nAMD, neovascular age-related macular degeneration; OCT, optical coherence tomography.

1. Bressler NM *et al. Ophthalmology* 2004; 111 (11): 1993–2006; 2. Yiu G, Mahmoud TH. *Dev Ophthalmol* 2014; 54: 213–222;

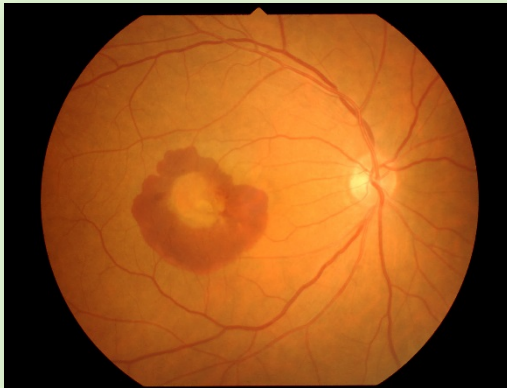3. Lin T-C *et al. J Chin Med Assoc* 2016; 79 (3): 159–165; 4. Scupola A *et al. Ophthalmologica* 1999; 213 (2): 97–102;

5. Bae K *et al. PLoS One* 2016; 11 (12): e0168474.

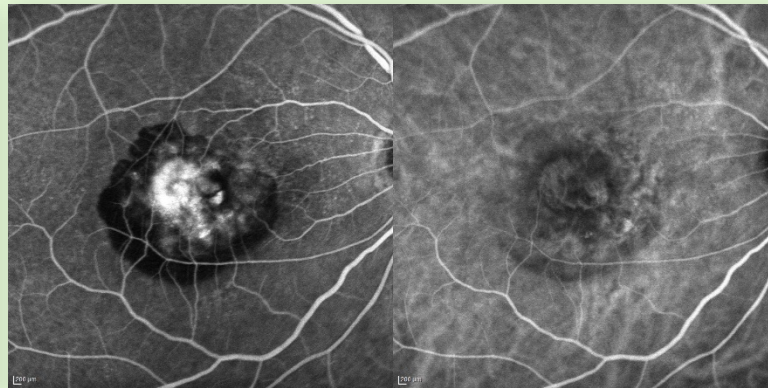
Imaging of subfoveal hemorrhage to determine hemorrhage size, thickness, and etiology

- **FA** may be of limited value in the acute phase because of the masking effect of subretinal blood
- **ICGA** utilizes infrared light to penetrate the RPE and blood, and may be more helpful than FA in detecting CNV or PCV lesions
- **OCT / OCT-A** helps to localize the hemorrhage within the retinal layers and can objectively quantify hemorrhage size
 - **EDI-OCT** provides further detailed imaging of the choroid

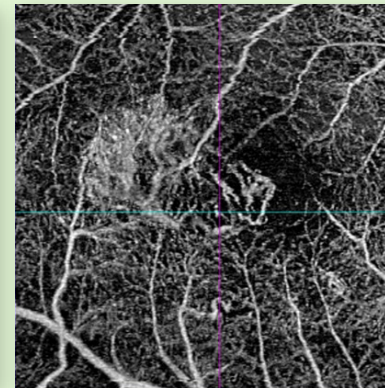
Fundus photography



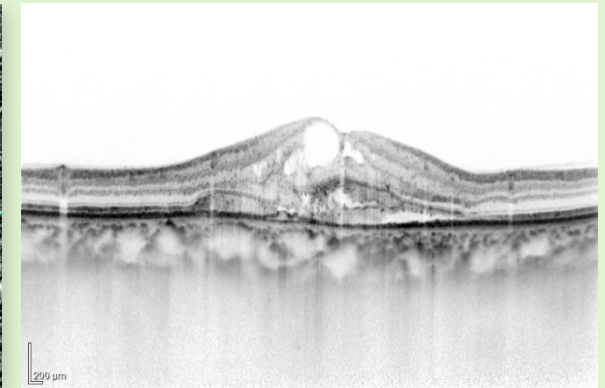
FA / ICGA



OCT-A



EDI-OCT




Images courtesy of Professor Annabelle Okada



CHALLENGE REQUIRING VISION ACADEMY GUIDANCE

What imaging types are recommended in patients with subfoveal hemorrhage?



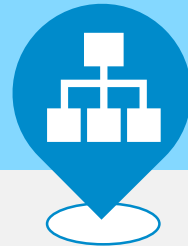

VISION ACADEMY
people | research | education

Treatment

Treatment challenges to be addressed

There is currently a lack of evidence-based research to inform the management of patients with subfoveal hemorrhage



Mixed evidence on the most appropriate treatments for subfoveal hemorrhage



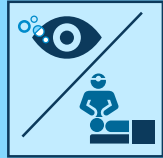
Mixed evidence on the criteria for initiating treatment of subfoveal hemorrhage

Treatment options

Click on a section



Potential treatments include:

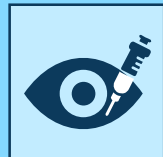

Intravitreal tPA with pneumatic displacement

- tPA is a protease enzyme which can lyse the clot¹
- Pneumatic displacement (PD) involves shifting the hemorrhage from beneath the fovea using the buoyancy of the gas to avoid irreversible damage to the photoreceptors and RPE layers²

With or without surgical intervention (e.g. pars plana vitrectomy)

- Removal of the vitreous, including the fluid containing the hemorrhage¹



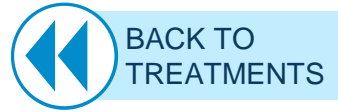Intravitreal anti-VEGF

- Antiangiogenic agents: ranibizumab, aflibercept

PD, pneumatic displacement; tPA, tissue plasminogen activator; VEGF, vascular endothelial growth factor.

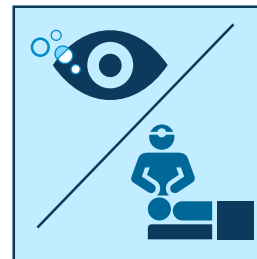
1. Lowe RJ *et al. Retinal Physician* 2011. Available at: <https://www.retinalphysician.com/issues/2011/june-2011/treatment-options-for-submacular-hemorrhage>.

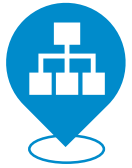Accessed July 23, 2018; 2. Bae K *et al. PLoS One* 2016; 11 (12): e0168474.



V I S I O N A C A D E M Y
people | research | education

Tissue plasminogen activator with pneumatic displacement





Positive visual outcomes have been demonstrated after 6 months of treatment with vitrectomy in combination with subretinal tPA in combination with PD or vitrectomy

Intravitreal or subretinal injection of tPA facilitates the removal of the dissolved clot when used in conjunction with intravitreal PD and/or surgical intervention¹

- A number of studies have demonstrated positive visual outcomes with tPA in conjunction with either PD or surgical intervention¹⁻⁵
- One study has demonstrated a lack of statistical significance between the two treatments, highlighting tPA with PD as a less invasive, less costly procedure than tPA with vitrectomy²

	logMAR VA			
	Initial vision	Month 1	Month 3	Month 6
Vitrectomy with subretinal tPA	1.8 ± 0.53	1.1 ± 0.5	1.0 ± 0.7	0.9 ± 0.6
Intravitreal tPA with PD	1.5 ± 0.51	1.0 ± 0.4	0.9 ± 0.5	0.9 ± 0.4
Pneumatic displacement	1.5 ± 0.45	1.3 ± 0.5	1.6 ± 0.4	1.6 ± 0.5


Fassbender JM *et al. Retina* 2016; 36 (10): 1860–1865

Both ppV and PD in combination with tPA resulted in positive visual outcomes after 6 months of treatment



CHALLENGE REQUIRING VISION ACADEMY GUIDANCE

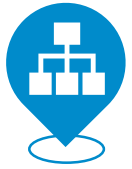When should tPA and PD be used? When should surgical intervention be considered?



logMAR, logarithm of the minimum angle of resolution; PD, pneumatic displacement; ppV, pars plana vitrectomy; tPA, tissue plasminogen activator; VA, visual acuity.

1. Stanescu-Segall D *et al. Surv Ophthalmol* 2016; 61 (1): 18–32; 2. Bell JE *et al. Ophthalmic Surg Lasers Imaging Retina* 2017; 48 (1): 26–32;
3. Fujikawa M *et al. Retina* 2013; 33 (9): 1908–1914; 4. Chang W *et al. Am J Ophthalmol* 2014; 157 (6): 1250–1257;
5. Fassbender JM *et al. Retina* 2016; 36 (10): 1860–1865.

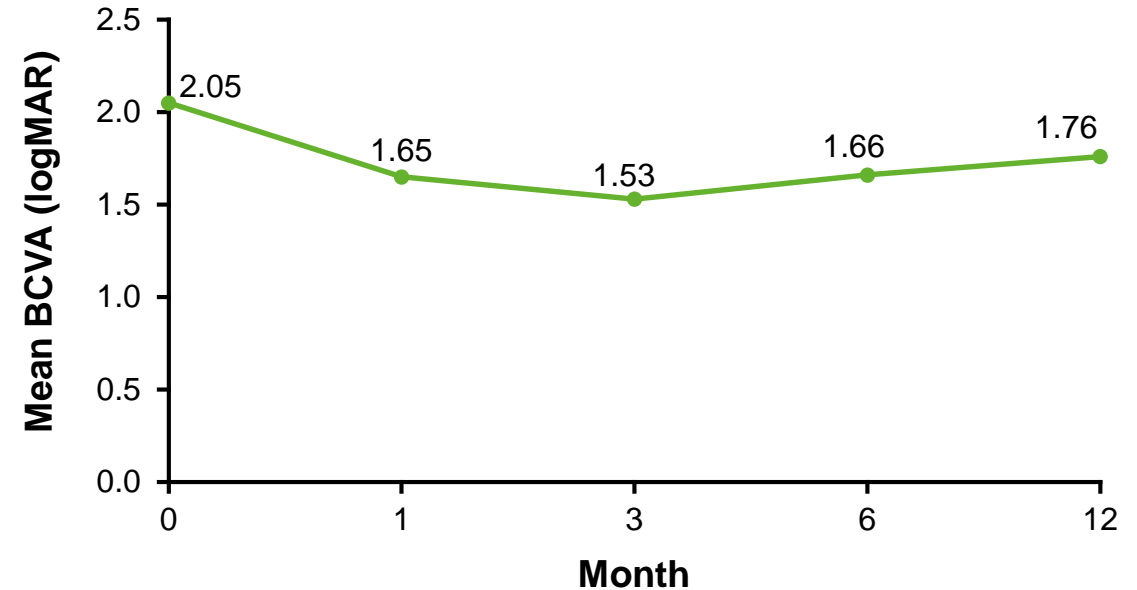




Vitreectomy with subretinal tPA and PD has been shown to result in positive visual outcomes and complete displacement of the hemorrhage


- **Chang *et al.* (2014):** Retrospective interventional case series of 101 patients presenting with thick submacular hemorrhage secondary to nAMD
- Patients underwent displacement of the hemorrhage (ppV), plus subretinal tPA with PD
 - VA significantly improved from baseline to Month 12 ($p=0.002$)
 - In 83 eyes, the procedure resulted in complete displacement of the hemorrhage from the fovea
- **Vitreectomy with subretinal tPA and PD has been shown to be an effective therapeutic option for thick submacular hemorrhage involving the fovea**

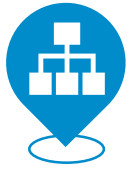Mean BCVA in patients during follow-up after undergoing pars plana vitrectomy with tPA and PD



CHALLENGE REQUIRING VISION ACADEMY GUIDANCE

When should surgical intervention in combination with tPA and PD be considered?





Summary and discussion

Evidence has demonstrated favorable visual outcomes with intravitreal tPA plus PD (both with and without vitrectomy) compared with PD alone for the treatment of subfoveal hemorrhage¹

Limitations of data:

- Impact of hemorrhage size and location on choice of treatment combination still unknown
- tPA plus PD appears to offer a less invasive, less costly alternative to vitrectomy; however further studies are needed
- Clear guidance on treatment choice is still lacking, due to a lack of consensus among studies



CHALLENGE REQUIRING VISION ACADEMY GUIDANCE


When should tPA and PD be used alone? When should the addition of surgical intervention be considered?



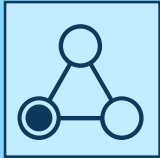

VISION ACADEMY
people | research | education

Intravitreal anti-VEGF therapy

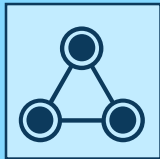


Treatment with intravitreal anti-VEGF for patients with subfoveal hemorrhage



Intravitreal anti-VEGF monotherapy

- Antiangiogenic agents are the standard of care for nAMD
 - Anti-VEGF agents have been shown to help clear intravitreal hemorrhage in diabetic retinopathy
- Monotherapy may be particularly relevant for patients not suited for PD, tPA, or surgery
 - Patients unable to maintain prone positioning



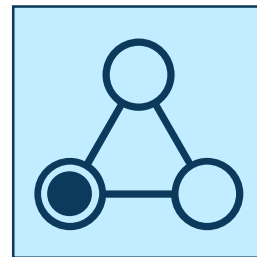
Intravitreal anti-VEGF combination therapy

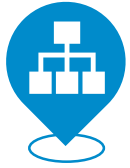In combination, it is believed that anti-VEGF therapy can control the underlying cause of the disease (CNV), while treatments such as vitrectomy, tPA, and PD can be applied to clear the hemorrhage



VISION ACADEMY
people | research | education

Intravitreal anti-VEGF monotherapy





A number of small studies have demonstrated positive visual outcomes with intravitreal anti-VEGF monotherapy


- A number of studies have reported positive visual outcomes with anti-VEGF monotherapy for the treatment of submacular hemorrhage, including subfoveal hemorrhage, secondary to nAMD
- However, small sample sizes and differences in baseline features and treatment regimens limit direct comparison of these results¹

	Shienbaum <i>et al.</i> 2013 ¹	Kim <i>et al.</i> 2014 ²	Iacono <i>et al.</i> 2014 ³	Liu <i>et al.</i> 2017 ⁴ <i>subfoveal specific</i>	Shin <i>et al.</i> 2016 ⁵ <i>subfoveal specific</i>
Study country	USA	Korea	Italy	USA	Korea
Number of eyes	15	71	23	47	25
Follow-up period, months	6	12	12	12	6
Extent of baseline hemorrhage (range)	>50% of lesion area (4.3–170.2 mm ²)	<50%–>50% of lesion area (3–20 disc areas)	>50% of lesion area	'Large submacular hemorrhage' (7.3–96.6 mm ²)	<50% of lesion area (2.7–25.6 mm ²)
Anti-VEGF agent	Ranibizumab and/or bevacizumab*	Ranibizumab and/or bevacizumab*	Ranibizumab	Ranibizumab or bevacizumab*	Aflibercept
Change in BCVA from baseline:					
Gain of ≥3 lines / ≥15 letters, n (%)	9 (60.0)	46 (64.8)	8 (34.7)	27 (57.0)	11 (44.0)
Maintained stable vision, n (%)	6 (40.0)	21 (29.6)	2 (8.7)	14 (30.0)	13 (52.0)
Loss of ≥3 lines / ≥15 letters, n (%)	0	4 (5.6)	2 (8.7)	6 (13.0)	1 (4.0)



CHALLENGE REQUIRING VISION ACADEMY GUIDANCE

When is anti-VEGF monotherapy recommended?



*Bevacizumab is not licensed for the treatment of visual impairment due to nAMD. Table adapted from Shin *et al.* 2016.⁵
BCVA, best corrected visual acuity; nAMD, neovascular age-related macular degeneration; VEGF, vascular endothelial growth factor.

1. Shienbaum G *et al.* *Am J Ophthalmol* 2013; 155 (6): 1009–1013; 2. Kim JH *et al.* *Ophthalmology* 2014; 121 (4): 926–935;
3. Iacono P *et al.* *Retina* 2014; 34 (2): 281–287; 4. Liu EM *et al.* *J Vitreoretin Dis* 2017; 1 (1): 34–40; 5. Shin K-H *et al.* *Korean J Ophthalmol* 2016; 30 (5): 369–376.





Ranibizumab has demonstrated effectiveness in patients with good baseline vision and shorter disease duration

- **Iacono et al. (2014):** Prospective interventional case series of 23 patients presenting with occult CNV with flat submacular hemorrhage, of whom six had foveal involvement
- Patients were treated with three monthly injections of intravitreal **ranibizumab**, with re-treatment given over a 12-month follow-up period on a PRN basis
- **Mean BCVA significantly increased** throughout the follow-up period from 0.82 ± 0.22 to 0.68 ± 0.41 ($p=0.04$)
- Subgroup analysis of baseline **presence of blood in the foveal region** disclosed a **deterioration of BCVA** from 0.96 ± 0.10 to 1.15 ± 0.23 at 12 months in eyes with foveal hemorrhages ($p=0.03$)
- Conversely, subjects with **initial foveal sparing** showed a **significant improvement** in BCVA, ranging from 0.77 ± 0.23 at baseline to 0.52 ± 0.33 at 12 months ($p=0.01$)

However, poor visual outcomes were seen in eyes with submacular hemorrhages involving the fovea



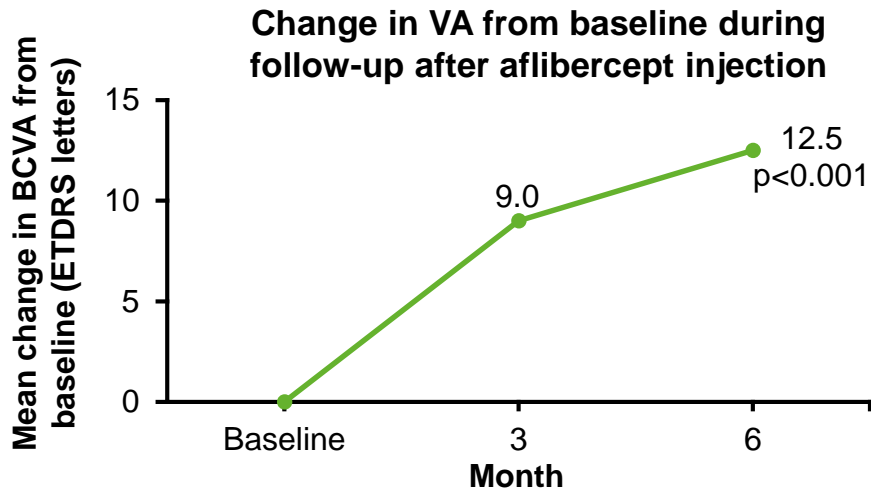
CHALLENGE REQUIRING VISION ACADEMY GUIDANCE

When should anti-VEGF monotherapy be used to treat subfoveal hemorrhage?

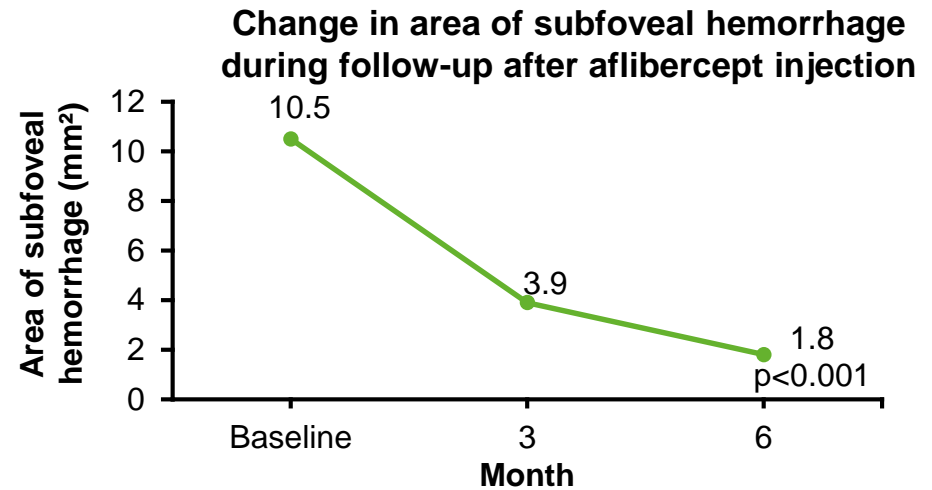


Aflibercept has been shown to increase VA and decrease hemorrhage size over 6 months of treatment

- **Shin et al. (2016):** Retrospective observational case series of 25 patients presenting with subfoveal hemorrhage secondary to nAMD
- Patients treated with three monthly injections of intravitreal **aflibercept**, with re-treatment given over a 6-month follow-up period on a PRN basis
- However, further studies are required to determine its effectiveness in treating eyes with subfoveal hemorrhage, and in cases where treatment is delayed



Vision significantly improved from baseline to Month 6 ($p < 0.001$)





Hemorrhage size significantly decreased from baseline to Month 6 ($p < 0.001$)



CHALLENGE REQUIRING VISION ACADEMY GUIDANCE

When should anti-VEGF monotherapy be used in cases of delayed treatment or subfoveal hemorrhages?



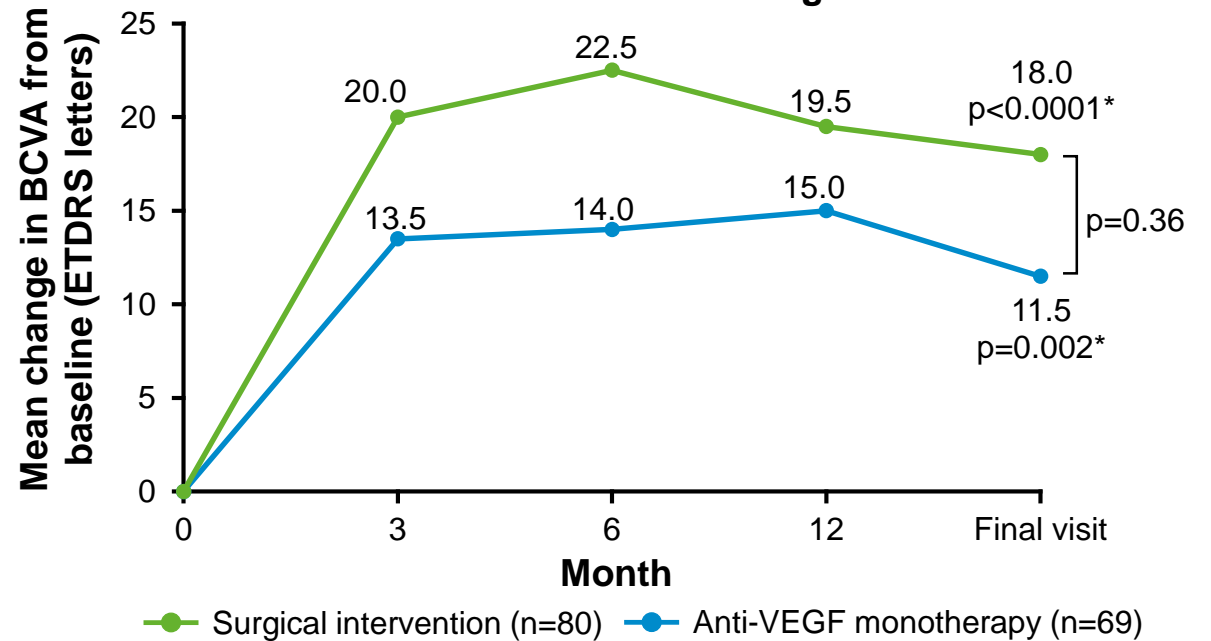


Similar improvements in BCVA have been demonstrated with anti-VEGF monotherapy vs. combination treatment with vitrectomy, tPA and pneumatic displacement

- **Liu et al. (2017):** Retrospective study of 149 patients presenting with large subfoveal hemorrhage secondary to nAMD, receiving intravitreal anti-VEGF monotherapy or combined treatment of ppV with tPA and PD
- At baseline, patients in the surgical group had larger hemorrhages than those in the anti-VEGF monotherapy group (30.35 mm² vs. 14.47 mm²) and worse baseline vision (4.5 letters vs. 20.5 letters)
- Despite these baseline differences, the mean change in VA between the two study groups at the final visit was not statistically significant (p=0.36)


Although differences in the treatment groups make comparisons difficult, the two study groups show similar improvements in BCVA

Change in VA from baseline in patients treated with anti-VEGF monotherapy vs. surgical intervention for subfoveal hemorrhage



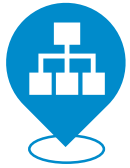CHALLENGE REQUIRING VISION ACADEMY GUIDANCE

When is anti-VEGF monotherapy preferred over surgical intervention?



*P values for mean change in BCVA at final visit versus baseline.

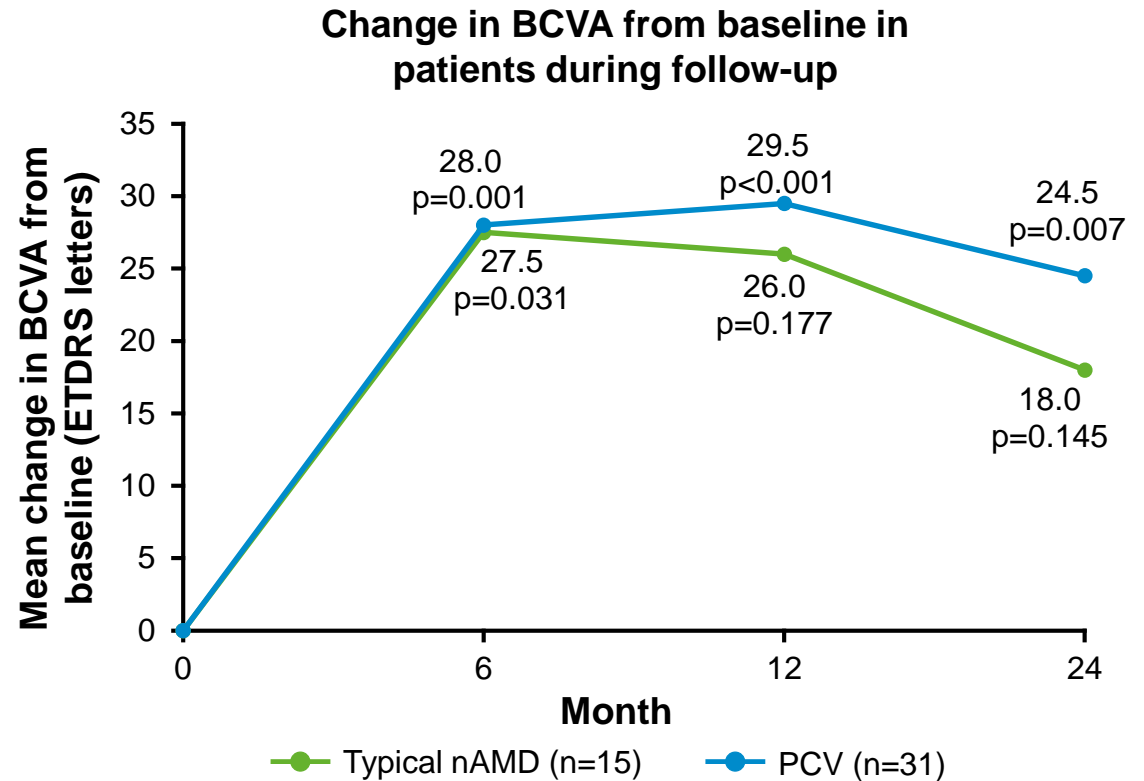
BCVA, best corrected visual acuity; ETDRS, Early Treatment Diabetic Retinopathy Study; nAMD, neovascular age-related macular degeneration; PD, pneumatic displacement; ppV, pars plana vitrectomy; tPA, tissue plasminogen activator; VA, visual acuity; VEGF, vascular endothelial growth factor.
Liu EM et al. *J Vitreoretin Dis* 2017; 1 (1): 34–40.



Anti-VEGF monotherapy has been shown to consistently improve VA for more than 2 years in patients with submacular hemorrhage due to PCV


- **Kim et al. (2015):** Retrospective observational study of 49 patients who initially presented with typical nAMD; 31 were later classified as having PCV*
- Patients were treated with either intravitreal **bevacizumab**[†] or intravitreal **ranibizumab**
- In the PCV group, significant improvements in BCVA from baseline were seen at Month 12 ($p<0.001$) and at Month 24 ($p=0.007$)
- Improvements in VA from baseline were seen for more than 2 years with anti-VEGF monotherapy
 - However, there was no common treatment protocol or follow-up examination schedule

Anti-VEGF therapy resulted in significant improvements in BCVA from baseline in patients with PCV



CHALLENGE REQUIRING VISION ACADEMY GUIDANCE

When should anti-VEGF monotherapy be used in patients with PCV?



*A definitive diagnosis was not possible in three patients. [†]Bevacizumab is not licensed for the treatment of retinal diseases. BCVA, best corrected visual acuity; ETDRS, Early Treatment Diabetic Retinopathy Study; nAMD, neovascular age-related macular degeneration; PCV, polypoidal choroidal vasculopathy; VA, visual acuity; VEGF, vascular endothelial growth factor. Kim KH et al. *Korean J Ophthalmol* 2015; 29 (5): 315–324.

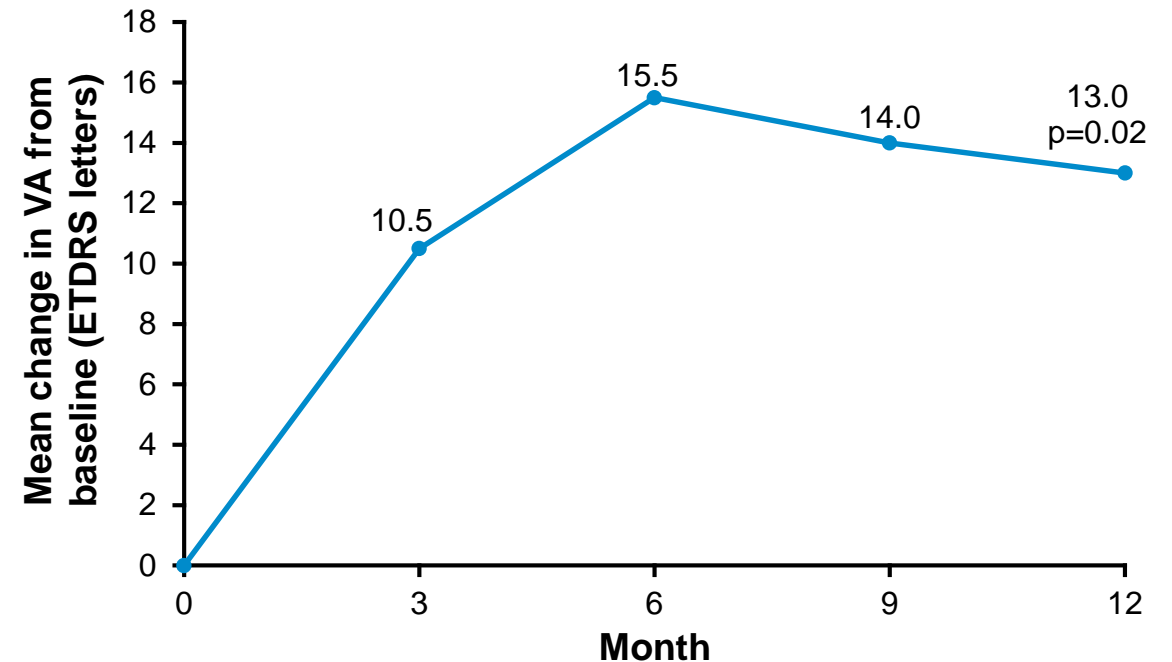




Intravitreal anti-VEGF has been shown to increase VA from baseline to Month 12 in patients with PCV


- **Cho et al. (2013):** Retrospective interventional study of 27 patients presenting with subfoveal hemorrhage secondary to PCV
- Patients treated with three initial monthly loading doses of intravitreal **bevacizumab*** or intravitreal **ranibizumab**, followed by re-treatment on a PRN basis
- VA was significantly improved from baseline to Month 12 ($p=0.02$)
- **Intravitreal anti-VEGF therapy was shown to be a valuable therapeutic option**

Change in VA from baseline in patients during follow-up after anti-VEGF treatment



CHALLENGE REQUIRING VISION ACADEMY GUIDANCE

When should anti-VEGF monotherapy be used in patients with PCV?



*Bevacizumab is not licensed for the treatment of visual impairment due to PCV.

ETDRS, Early Treatment Diabetic Retinopathy Study; PCV, polypoidal choroidal vasculopathy; PRN, *pro re nata* (as needed); VA, visual acuity; VEGF, vascular endothelial growth factor.

Cho HJ et al. *Am J Ophthalmol* 2013; 156 (3): 524–531.e1.





Prompt initiation of treatment is needed

Studies have demonstrated that intravitreal anti-VEGF results in better visual outcomes in patients with better baseline vision and shorter hemorrhage duration¹⁻³

This suggests that in patients with subfoveal hemorrhage and nAMD, intravitreal anti-VEGF treatment should be initiated promptly



CHALLENGE REQUIRING VISION ACADEMY GUIDANCE

When should anti-VEGF treatment be initiated?



nAMD, neovascular age-related macular degeneration; VEGF, vascular endothelial growth factor.

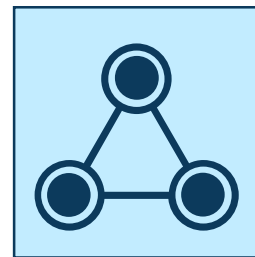
1. Shin K-H *et al. Korean J Ophthalmol* 2016; 30 (5): 369–376; 2. Kim KH *et al. Korean J Ophthalmol* 2015; 29 (5): 315–324;
3. Liu EM *et al. J Vitreoretin Dis* 2017; 1 (1): 34–40.





VISION ACADEMY
people | research | education

Intravitreal anti-VEGF combination therapy





Retrospective studies have examined the effectiveness of intravitreal anti-VEGF therapy in combination with tPA, PD, and ppV


- A number of **retrospective case series** have reported positive visual outcomes with different treatment combinations for subfoveal hemorrhage secondary to nAMD

	Cho <i>et al.</i> 2015 ¹	Sacu <i>et al.</i> 2009 ²	de Silva <i>et al.</i> 2016 ³	Lee <i>et al.</i> 2016 ⁴	González-López <i>et al.</i> 2016 ⁵	Treumer <i>et al.</i> 2012 ⁶	Treumer <i>et al.</i> 2017 ⁷	Kitahashi <i>et al.</i> 2014 ⁸
Study country	Korea	Austria	UK	Korea	UK	Germany	Germany	Japan
Treatment	Ranibizumab + PD	Bevacizumab* / ranibizumab, tPA + PD	Bevacizumab* / ranibizumab, tPA + PD	Bevacizumab* / ranibizumab, TNK + PD	Vitrectomy, subretinal tPA + ranibizumab	ppV, tPA, PD + bevacizumab*	ppV, tPA, PD + bevacizumab* / ranibizumab	Bevacizumab* + PD
Number of eyes, n	93	20	8	25	45	41	132	22
Follow-up period, months	12	4	12	12	12	12	3	6
Mean change in BCVA from baseline to final follow-up visit, logMAR (ETDRS letters)	-0.23 (+11.5) [p=0.007]	-0.54 (+27.0) [p=0.003]	-1.04 (+52.0) [p<0.0001]	-0.57 (+28.5) [p<0.001]	-0.59 [p<0.001]	-0.9 (+45.0)	-0.6† (+30.0) [p<0.0001]	-0.32 (+20.6) [p<0.01]
Any improvement in vision, n (%)	NA	16 (80.0)	8 (100.0)	15 (60.0)	33 (73.3)	NA	96 (73.0)	18 (81.8)
Maintained stable vision, n (%)	NA	1 (5.0)	0	9 (36.0)	10 (22.2)	NA	20 (15.0)	4 (18.2)
Any worsening of vision, n (%)	NA	3 (15.0)	0	1 (4.0)	2 (4.4)	NA	16 (12.0)	0



CHALLENGE REQUIRING VISION ACADEMY GUIDANCE

When should anti-VEGF in combination with other treatments be used?



*Becavizumab is not licensed for the treatment of visual impairment due to nAMD. †Reported as median change in BCVA from baseline at final follow-up.

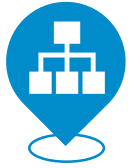BCVA, best corrected visual acuity; ETDRS, Early Treatment Diabetic Retinopathy Study; logMAR, logarithm of the minimum angle of resolution; NA, not available; nAMD, neovascular age-related macular degeneration; PD, pneumatic displacement; ppV, pars plana vitrectomy; TNK, tenecteplase; tPA, tissue plasminogen activator; VEGF, vascular endothelial growth factor.

1. Cho HJ *et al. Retina* 2015; 35 (2): 205–212; 2. Sacu S *et al. Eye (Lond)* 2009; 23 (6): 1404–1410; 3. de Silva SR *et al. Eye (Lond)* 2016; 30 (7): 952–957;

4. Lee JP *et al. Korean J Ophthalmol* 2016; 30 (3): 192–197; 5. González-López JJ *et al. Eye (Lond)* 2016; 30 (7): 929–935; 6. Treumer F *et al. Br J Ophthalmol* 2012; 96 (5): 708–713;

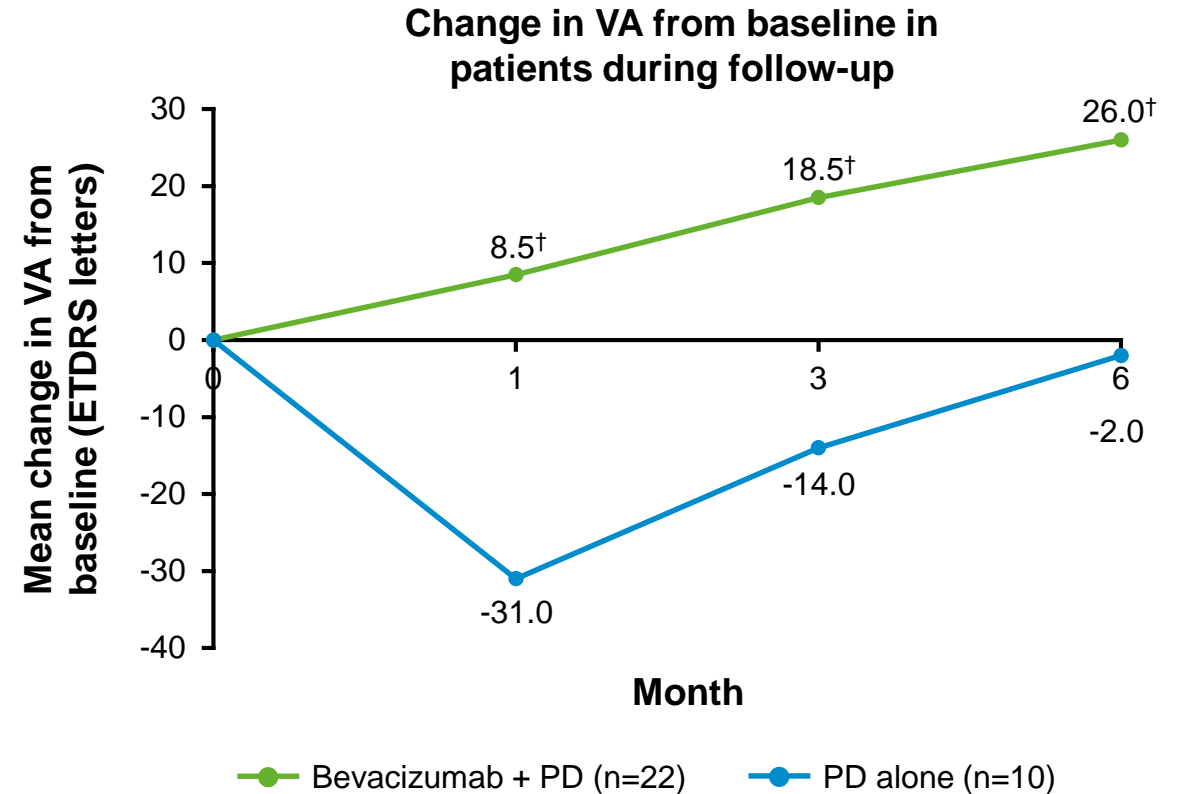
7. Treumer F *et al. Graefes Arch Clin Exp Ophthalmol* 2017; 255 (6): 1115–1123; 8. Kitahashi M *et al. Clin Ophthalmol* 2014; 8: 485–492.






Combination of anti-VEGF therapy and PD has been shown to improve visual outcomes in patients with PCV

- **Kitahashi *et al.* (2014):** Retrospective case series of 32 patients presenting with massive subfoveal hemorrhage secondary to PCV
- 22 patients were treated with intravitreal **bevacizumab*** and PD; 10 were treated with PD alone
- BCVA in the combination group was significantly better than that in the PD group at Months 1, 3, and 6 after treatment (all $p < 0.01$)
- **Combination of an anti-VEGF agent and PD was shown to be an effective therapeutic option for eyes with massive subfoveal hemorrhage**



CHALLENGE REQUIRING VISION ACADEMY GUIDANCE

When should anti-VEGF in combination with PD be used?



*Bevacizumab is not licensed for the treatment of visual impairment due to PCV. [†]Bevacizumab + PD versus PD alone, $p < 0.01$.
BCVA, best corrected visual acuity; ETDRS, Early Treatment Diabetic Retinopathy Study; PCV, polypoidal choroidal vasculopathy; PD, pneumatic displacement;
VA, visual acuity; VEGF, vascular endothelial growth factor.
Kitahashi M *et al.* *Clin Ophthalmol* 2014; 8: 485–492.

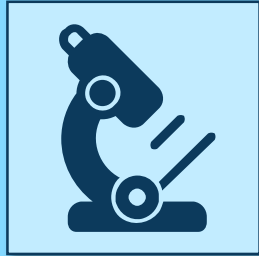



VISION ACADEMY
people | research | education


Clinical challenges

Clinical challenges requiring guidance




Imaging

- Which imaging techniques should be used in patients with subfoveal hemorrhage to determine hemorrhage size?



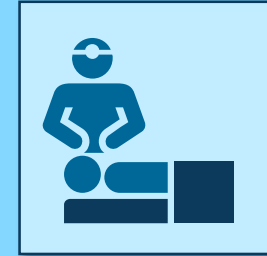
Intravitreal anti-VEGF treatment

- Should intravitreal anti-VEGF treatment be administered? When should treatment be initiated?



tPA and PD

- When is treatment with tPA and PD appropriate?



Surgical intervention

- When should surgical intervention be considered?



VISION ACADEMY
people | research | education

Vision Academy recommendations

Multimodal imaging with OCT is recommended



Important tools to distinguish between subretinal and sub-RPE blood, and for objectively quantifying hemorrhage size:¹

- Color fundus photography
- Fundus autofluorescence
- Spectral domain OCT (including use of the enhanced depth imaging mode)
- ICGA



These imaging tools can help determine hemorrhage size, thickness, location of blood (above or below the RPE) and etiology²⁻⁵



Multimodal imaging with OCT should be used to determine several prognostic factors for subfoveal hemorrhage²⁻⁵



General consensus

ICGA, indocyanine green angiography; OCT, optical coherence tomography; RPE, retinal pigment epithelium.
 1. Stanescu-Segall D *et al. Surv Ophthalmol* 2016; 61 (1): 18–32; 2. Yiu G, Mahmoud TH. *Dev Ophthalmol* 2014; 54: 213–222;
 3. Scupola A *et al. Ophthalmologica* 1999; 213 (2): 97–102; 4. Karagiannis D *et al. Clin Interv Aging* 2017; 12: 1829–1833;
 5. Lin T-C *et al. J Chin Med Assoc* 2016; 79 (3): 159–165.

Prompt initiation of anti-VEGF with careful monitoring is recommended as a first-line treatment for subfoveal hemorrhage in nAMD and PCV



- In patients with nAMD and subfoveal hemorrhage, anti-VEGF should be promptly initiated to minimize the risk of irreversible retinal damage
- In eyes with good baseline vision and short hemorrhage duration, significant visual improvements were observed with anti-VEGF treatment¹⁻³
- Careful monitoring is important for the early detection of breakthrough hemorrhage to minimize the risk of complications



The importance of early detection and initiation of anti-VEGF treatment was demonstrated in studies showing significant visual improvements in eyes with good baseline vision and short hemorrhage duration¹

Anti-VEGF treatment is recommended for patients able to attend regular follow-up appointments



General consensus

Intravitreal tPA with PD is recommended for patients, depending on the thickness of the subfoveal hemorrhage



- Evidence has demonstrated favorable visual outcomes with intravitreal tPA plus PD (both with and without vitrectomy) compared with PD alone for the treatment of subretinal hemorrhage¹

- While a sub-RPE hemorrhage in association with a subretinal hemorrhage involving the fovea does not preclude the use of PD or vitrectomy, the location and size of the sub-RPE component may affect the decision to perform these procedures



Studies have demonstrated positive visual outcomes in patients treated with tPA in combination with PD or vitrectomy¹⁻⁵

Intravitreal tPA with PD and intravitreal anti-VEGF therapy is recommended for medium, large, or thick subfoveal hemorrhages in patients with poor baseline vision (<20/200), at the discretion of the physician



General consensus

PD, pneumatic displacement; RPE, retinal pigment epithelium; tPA, tissue plasminogen activator.

1. Stanescu-Segall D *et al. Surv Ophthalmol* 2016; 61 (1): 18–32; 2. Chang W *et al. Am J Ophthalmol* 2014; 157 (6): 1250–1257;
3. Bell JE *et al. Ophthalmic Surg Lasers Imaging Retina* 2017; 48 (1): 26–31; 4. Fujikawa M *et al. Retina* 2013; 33 (9): 1908–1914;
5. Fassbender JM *et al. Retina* 2016; 36 (10): 1860–1865.



Surgical intervention is recommended only for severe hemorrhages



- Evidence suggests that ppV in combination with subretinal tPA, PD, and intravitreal anti-VEGF therapy may offer a more effective option than anti-VEGF monotherapy for the treatment of patients with thick or large hemorrhages and poor baseline vision^{1,2}

- However, without adequate prospective studies, it is not possible to draw comparisons between surgery and other treatment modalities because of likely variation in surgical techniques between reports







Surgical intervention may offer a more effective option than anti-VEGF monotherapy for the treatment of thick or large hemorrhage in eyes with poor baseline vision,^{1,2} but additional studies are warranted

The Vision Academy recommends surgical intervention only for severe subretinal hemorrhages, as determined by thickness and location



General consensus

Vision Academy recommendations for the management of subfoveal hemorrhage

-  Multimodal imaging with OCT is recommended to determine several prognostic factors for subfoveal hemorrhage, including hemorrhage, size, thickness, location and etiology, in order to drive treatment choice
-  Prompt initiation of anti-VEGF with careful monitoring is recommended as a first-line treatment for subfoveal hemorrhage in nAMD and PCV
-  Intravitreal tPA in conjunction with PD and anti-VEGF therapy is recommended for medium, large, or thick subfoveal hemorrhage in patients with poor baseline vision (<20/200)
-  Surgical intervention with subretinal tPA is recommended only in severe cases, as determined by hemorrhage thickness and location

The Viewpoint 'Management of subfoveal hemorrhage' can be downloaded from:
<https://www.visionacademy.org/resource-zone/treatment-best-practices>

Further considerations

Additional larger studies are required to investigate the efficacy of anti-VEGF, as monotherapy or in combination with other treatment modalities, for the management of subfoveal hemorrhage in nAMD



Treatment decisions may be affected by regional variations in reimbursement policies; however, the decision to treat should be based primarily on clinical experience and consideration of the available evidence

